

Antiulcer Properties of Kelulut Honey against Ethanol-Induced Gastric Ulcer

Latifah Saiful Yazan^{1,2*}, Nurul Amira Zainal¹, Razana Mohd Ali²,
Muhamad Firdaus Shyfiq Muhamad Zali¹, Ong Yong Sze³, Tor Yin Sim³,
Banulata Gopalsamy¹, Voon Fui Ling¹, Sarah Sapuan³, Nurulaidah Esa³,
Aminah Suhaila Haron¹, Fatin Hannani Zakarial Ansar³,
Ana Masara Ahmad Mokhtar¹ and Sharifah Sakinah Syed Alwi¹

¹Department of Biomedical Science, Faculty of Medicine and Health Sciences, Universiti Putra Malaysia, 43400 UPM, Serdang, Selangor, Malaysia

²Department of Pathology, Faculty of Medicine and Health Sciences, Universiti Putra Malaysia, 43400 UPM, Serdang, Selangor, Malaysia

³Laboratory of Molecular Biomedicine, Institute of Bioscience, Universiti Putra Malaysia, 43400 UPM, Serdang, Selangor, Malaysia

ABSTRACT

Ulcers in the gastrointestinal tract refer to any appreciable depth of break in the mucosa lining that may involve submucosa. Common types of ulcer include peptic, gastric and duodenal ulcer, which may lead to chronic inflammation. Ulcers may be caused by excessive alcohol intake or prolonged use of non-steroidal anti-inflammatory drugs (NSAID), in addition to several other factors. Conventional medication such as Omeprazole (proton pump inhibitor) and Ranitidine (H₂ blockers) for management

of ulcers may cause severe side effects such as myelosuppression and abnormal heart rhythm. This has driven researchers to explore the potential of natural products for management of ulcers with reduced side effects. Kelulut honey (KH) is a type of honey that is produced by stingless bees from the *Trigona* species. It is believed to have a lot of medicinal properties such as being antimicrobial, antioxidant and antidiabetic. Yet, no scientific study has been carried out on its antiulcer properties. This study was carried out to determine the antiulcer properties of KH. Eighteen male *Sprague dawley* rats (5 to 6 weeks old, weighing between 200 and 300 g) were divided into three groups (n=6). The groups were 1) normal control group (without ulcer, without KH), 2) positive control group (with ulcer, without KH) and 3) treatment group (with

ARTICLE INFO

Article history:

Received: 24 November 2016

Accepted: 17 August 2017

E-mail addresses:

latifahsy@upm.edu.my (Latifah Saiful Yazan),
ieramyra_92@yahoo.com (Nurul Amira Zainal),
razanamohdali71@gmail.com (Razana Mohd Ali),
firdaus_shyfiq@yahoo.com
(Muhamad Firdaus Shyfiq Muhamad Zali),
ysooong_@hotmail.com (Ong Yong Sze),
yinsimtor@gmail.com (Tor Yin Sim),
banulatagopalsamy@yahoo.com (Banulata Gopalsamy),
voonfuiling@gmail.com (Voon Fui Ling),
sarajhr@yahoo.com (Sarah Sapuan),
nurulaidahesa@yahoo.com.my (Nurulaidah Esa),
aminahsuhaila91@gmail.com (Aminah Suhaila Haron),
fatinhannaniZA@yahoo.com (Fatin Hannani Zakarial Ansar),
anamasara@ymail.com (Ana Masara Ahmad Mokhtar),
sh_sakinah@upm.edu.my (Sharifah Sakinah Syed Alwi)

*Corresponding Author

ulcer, treated with KH). The treatment, KH (1183 mg/kg), was given twice daily for 30 consecutive days by oral administration. On Day 31, the rats were induced with absolute ethanol (5 mL/kg) via oral administration after being fasted for 24 h and were sacrificed 15 min after the induction. The stomach was collected for macroscopic and histopathological evaluation. Pretreatment with KH significantly reduced ($p < 0.05$) both the total area of ulcer and the ulcer index compared to the positive control group. The percentage of ulcer inhibition in the KH pre-treated group was 65.56% compared with the positive control group. The treatment, KH, exhibited antiulcer properties against ethanol-induced gastric ulcer.

Keywords: Kelulut honey (KH), antiulcer, gastric ulcer

INTRODUCTION

The term 'ulcer' was first introduced in 1882 by Quike (Clinch, 1989). According to the 'Global Burden of Disease, 2004', 270,000 cases worldwide were reported on peptic ulcer (Mathers et al., 2008) and 360 cases at a ratio of 1:1 of duodenal ulcer to gastric ulcer reported in Malaysia by the Profile of Peptic Ulcer Disease (Kudva, 1988). Peptic ulcer is the most common ulcer presenting as a benign lesion that occurs mainly due to excessive acid and pepsin bathing the surface of the mucosa (Pillai et al., 2010). It can develop in different parts of the gastrointestinal tract such as the stomach as gastric ulcers and the duodenum as duodenal ulcers. Primarily, there are two major etiologies of peptic ulcer, infection by *Helicobacter pylori* and excessive intake of non-steroidal anti-inflammation agents (NSAIDs). Other contributory factors are smoking and nutritional deficiencies (Rang et al., 2014; Naesdal & Brown, 2006). Ulcers are usually detected upon symptoms such as burning epigastric pain that may occur before or after meals, bloating, fullness and nausea. In severe condition, this may lead to complications such as perforation and bleeding (Malfertheiner et al., 2009).

There are various classes of medication available for ulcer management including the Histamine-2 receptor antagonist such as cimetidine and ranitidine, proton-pump inhibitors such as omeprazole and esomeprazole and prostaglandin E analogues such as misoprostol (Chan & Lau, 2010). However, all these drugs may lead to several side effects such as nausea (Dharmani, 2006), headache, abnormal heart rhythm and myelosuppression (Sandhya et al., 2013). Thus, it is important to continue searching for safer and more effective antiulcer drugs among natural products.

One of the potential candidates is Kelulut honey (KH), which is produced from bees of the *Trigona* sp. more commonly known as Kelulut bees in Malaysia. A characteristic that differs *Trigona* sp. from common bees of other species is that it is stingless. Honey contains roughly 80% carbohydrates (35% glucose, 40% fructose and 5% sucrose) and 20% water, serving as a great source of energy. Moreover, it also contains more than 180 substances, including amino acids, vitamins, minerals, organic acid phenol compounds and enzymes. The pH of honey is around 4.0 (Ouchemoukh et al., 2007). Traditionally, KH is used in treatments for anti-ageing, fast healing of internal injuries and cough and cold (Barakhbah, 2007). KH was also reported to have various pharmacological effects such as anti-diabetes, antioxidant and antibacterial (Siok

et al., 2014; Zainol et al., 2013). Antioxidation is considered to be associated with anti-ulcer properties (Bashkaran et al., 2011). The phenolic compound that is one of the phytochemicals found in propolis is believed to contribute to the antiulcer activity (Pillai et al., 2010) as it has strong correlation with antioxidant activity (Bertoncelj et al., 2007; Beretta et al., 2005; Meda et al., 2005). This study was carried out to determine the antiulcer properties of KH.

METHODOLOGY

Chemicals and Reagents

Formalin was purchased from Fisher Scientific, UK. Absolute alcohol was purchased from Sigma Aldrich, USA. Hematoxylin and eosin were purchased from CellPath, UK. Xylene was purchased from Jt Baker, USA. Kelulut honey (KH) was provided by Marbawi Food Processing and Trading, Kuala Kangsar, Perak.

Experiment Animals

Eighteen male *Sprague dawley* rats with initial weight approximately 200-300 g at the age of 5-6 weeks old were acclimatised with free access to standard chow pellets and water for about one week before the study. For animal husbandry, three rats were been placed in a cage. This study was conducted after obtaining ethical approval (FYP.2015/FPSK.001) from the Institutional Animal Care and Used Committee (IACUC) of Universiti Putra Malaysia.

Experiment Procedure

Following acclimatisation, the rats were divided randomly into three groups (n=6) as detailed below.

Group 1: Negative control group (without ulcer, without KH)

Group 2: Positive control group (with ulcer, without KH)

Group 3: Treatment group (with ulcer, with KH)

The animals were pre-treated with KH twice daily via oral administration at the dosage of 1183.33 mg/kg body weight of rat for 30 days. This dosage was calculated based on human consumption.

The body weight of the rats was recorded every 3 days until the day of termination. On Day 30, the rats were fasted for 24 hours. On the following day, the rats in Groups 2 and 3 were induced with absolute ethanol (5 mL/kg body weight of rat) via oral administration for an hour after the last treatment of KH. Fifteen minutes later, all the rats were anesthetised with ketamine-xylazine (75 mg/kg body weight of rat: 5 mg/kg body weight of rat) by intra-peritoneal injection. Approximately 5 mL of blood was collected via cardiac puncture using a 26 G, ½” needle (Terumo®, Belgium, Europe) into a non-heparinised and EDTA-containing tube for biochemical and hematological analyses, respectively. The blood that was collected in the non-heparinised tube was centrifuged at 780 x g for 10 min to separate the serum. For the

histopathological analysis, the stomach was removed, cut open through its greater curvature and placed on graph paper to be captured by camera. Finally, the stomach was fixed in 10% formalin for further analysis.

Determination of the Ulcer Index and Inhibition

The ulcer index (UI) was calculated according to Goyal (2002) as follows:

$$\text{Ulcer index (UI)} = \frac{10}{X}$$

$$\text{where, X} = \frac{\text{Total area of the stomach}}{\text{Area of ulcer on the stomach}}$$

$$\text{Percentage of ulcer inhibition} = \frac{\text{UI of positive control} - \text{UI of treated group}}{\text{UI of positive control group}} \times 100$$

Histopathological Analysis

Initially, the samples of stomach tissue were grossed using a grossing blade (FEATHER Microtome Blade High Profile) by cutting the area of the ulcer from the opened stomach to get all the four layers. The grossed samples were placed in a cassette and processed using an automated tissue processor (Leica TP 1020, Germany) for 14 h during which they were dehydrated, cleared and infiltrated with paraffin wax.

Next, the processed tissue was embedded in appropriate orientation onto a block with molten paraffin wax using an embedder machine (Leica EG 1160, Germany). The block containing the tissue was then trimmed to thickness of 10 μm and sectioned to thickness of 0.4 μm using a microtome machine (Leica RM2135, Germany). The thin section of the tissue was placed in a water bath at 42°C. Next, the sample was fished onto slides and dewaxed before being stained with hematoxylin and eosin using an automated staining machine (Tissue-Tek® Prisma™, Japan) for 1 h and 18 min. The stained slides were mounted with P-xylene-bis-pyridinium bromide (DPX) and left to dry before being observed under a light microscope (Leica, Germany).

Statistical Analysis

All the data were analysed using Graph Pad Prism version 5.0. Analysis of the ulcer area and percentage of inhibition between the treated and untreated group was performed using the unpaired t-test. The differences in body weight were analysed by One Way ANOVA. The values are considered significant at $p < 0.05$.

RESULTS

Effect of Kelulut Honey on the Body Weight of the Rats

Figure 1 shows the body weight of the rats in the negative control, positive control and KH-treated groups throughout the experiment. The body weight of the rats in the three groups increased from Day 0 to Day 30. There was no significant difference ($p>0.05$) in the body weight of the rats among the groups throughout the experiment.

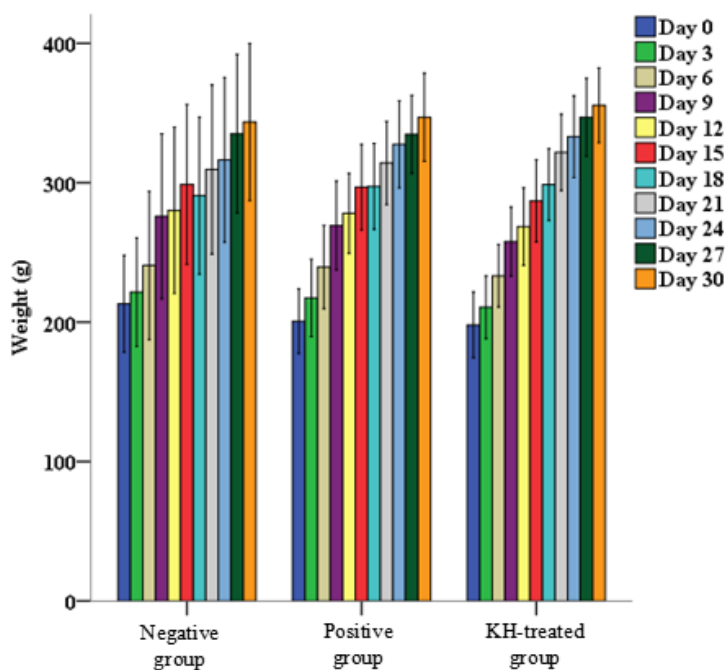


Figure 1. Effect of pretreatment with Kelulut honey for 30 days on the body weight of the rats. The data were analysed using One Way ANOVA and the values were expressed as Mean \pm S.E.M. The value of $p<0.05$ was considered significant

Hematology Profile of Ethanol-Induced Gastric Ulcer in Rats

As shown in Figure 2, hematological analysis on the red blood cell (RBC), white blood cell (WBC), hemoglobin (Hb), thrombocytes, packed cell volume (PCV), mean corpuscular volume (MCV) and mean corpuscular hemoglobin concentration (MGHC) exhibited no significant difference between the positive control, negative control and pretreated group ($p>0.05$).

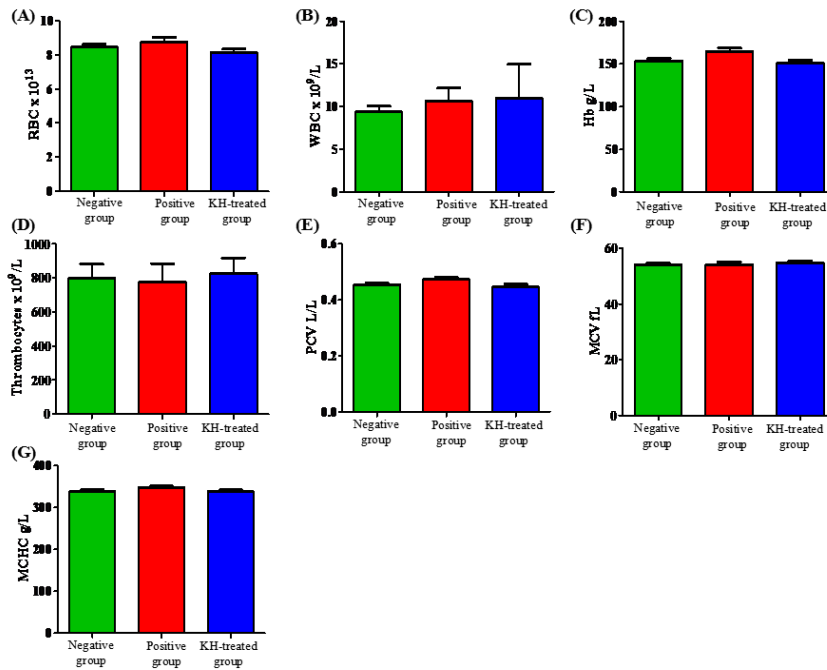


Figure 2. Effect of pretreatment with Kelulut honey for 30 days on the level of (A) RBC ($\times 10^{12}/L$), (B) WBC ($\times 10^9/L$), (C) Hb (g/L), (D) thrombocytes ($\times 10^9/L$), (E) PCV (L/L), (F) MCV (fL), (G) MCHC (g/L) in the ethanol-induced gastric ulcer rats. The negative control group (without ulcer, without pretreatment) and positive control group (with ulcer, without pretreatment) were also included. The data were analysed using One Way ANOVA and the values were expressed as Mean \pm S.E.M. The value of $p < 0.05$ was considered significant

Effect of Pretreatment with Kelulut Honey on the Level of Liver Enzymes and Kidney Functions in the Ethanol-Induced Gastric Ulcer Rats

Figure 3 shows the level of urea, creatinine, aspartate transaminase (AST) alanine transaminase (ALT) and alkaline phosphatase (ALP) in the ethanol-induced gastric ulcer rats that were untreated (positive control group) and pretreated with KH for 30 days. The negative control was also included. The level of AST in the positive control and KH-treated groups was significantly higher ($p < 0.05$) compared to the negative control group. Both levels of ALT and ALP showed no significant difference ($p < 0.05$) when compared among the groups.

Antiulcer Properties of Kelulut Honey

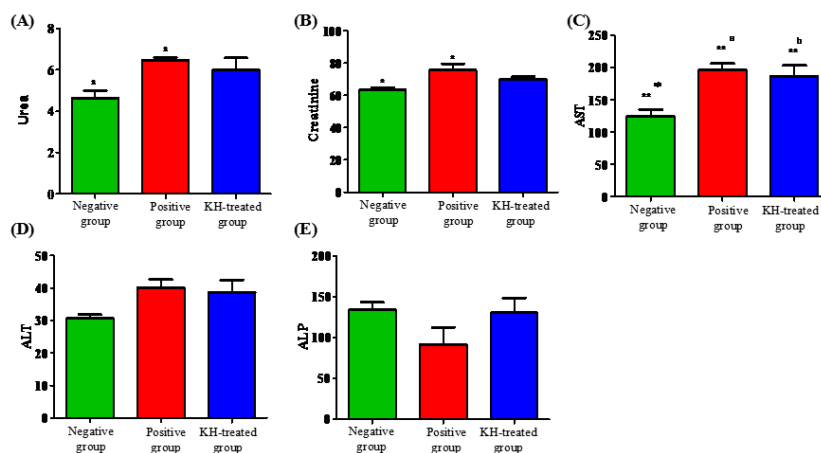


Figure 3. Effect of pretreatment with Kelulut honey for 30 days on the level of (A) urea (mmol/L), (B) creatinine ($\mu\text{mol/L}$), (C) AST (μL), (D) ALT (μL) and (E) ALP (μL) in the ethanol-induced gastric ulcer rats. The negative control group (without ulcer, without pretreatment) and positive control group (with ulcer, without pretreatment) were also included. The data were analysed using One Way ANOVA and the values were expressed as Mean \pm S.E.M. The value of $p < 0.05$ was considered significant

Effect of Pretreatment with Kelulut Honey on the Ulcer Area and Ulcer Index in the Ethanol-Induced Gastric Ulcer Rats

Figure 4 and Table 1 show the means of the ulcer area, ulcer index and percentage of ulcer inhibition in the stomach of the ethanol-induced gastric ulcer rats that were untreated (positive control group) and pretreated with KH for 30 days. There was a significant reduction ($p < 0.05$) in the mean ulcer area at a value of 89.00 ± 38.87 and in the ulcer index at a value of 1.346 ± 0.5293 in the group pretreated with KH compared to the positive control group. The percentage of ulcer inhibition in the KH-treated group was 68.56%.

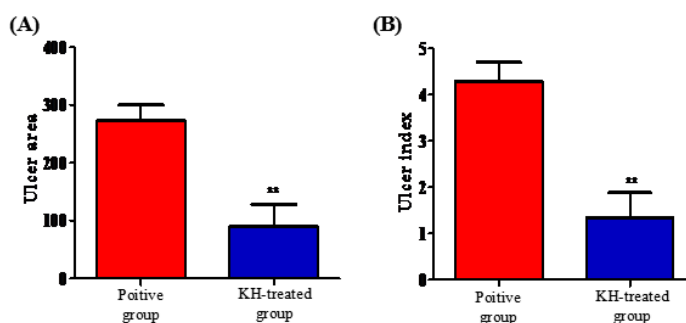


Figure 4. Effect of pretreatment with Kelulut honey for 30 days on the (A) ulcer area and (B) ulcer index in the ethanol-induced gastric ulcer rats. The positive control group (with ulcer, without pretreatment) was also included. The data were analysed using the unpaired t-test and the values were expressed as Mean \pm S.E.M. The value of $p < 0.05$ was considered significant

Table 1

Effect of pretreatment with kelulut honey on the ulcer area and ulcer index in ethanol-induced gastric ulcer rats between groups

Parameter	Positive Control Group (With Ulcer, Without KH Pretreatment)	Treatment Group (With Ulcer, with KH Pretreatment)	Percentage of Ulcer Inhibition (%)
Total Ulcer Area	272.4 ± 27.39	89.00 ± 38.87**	
Ulcer Index	4.281 ± 0.4157	1.346 ± 0.5293**	68.56

Note: All values were expressed as Mean ± S.E.M. The value of $p < 0.05$ was considered significant

Effect of Pretreatment with Kelulut Honey on the Gross Pathology of the Stomach of the Ethanol-Induced Gastric Ulcer Rats

Figure 5 shows the macroscopic images of the stomach from the negative control, positive control and KH-treated groups opened along the greater curvature. Diffuse severe hemorrhage and multifocal area of hemorrhage were noted on the surface area of the stomach from the positive control and KH-treated groups, respectively.

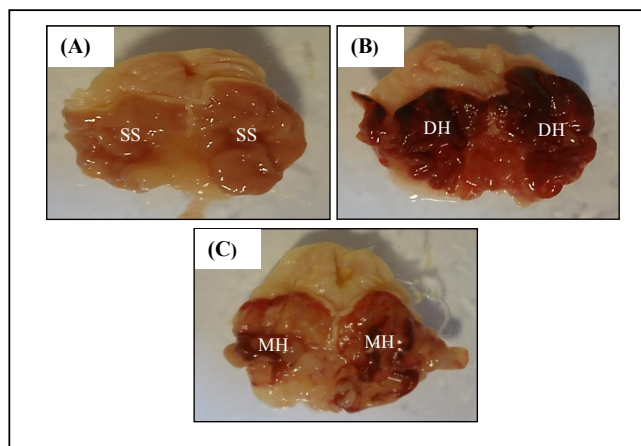


Figure 5. Macroscopic images of the stomach from (A) the negative control group with a smooth surface (SS), (B) positive control group with diffuse severe hemorrhage (DH) and (C) KH-treated group with the multifocal area of hemorrhage (MH) opened along the greater curvature

Effect of Pretreatment with Kelulut Honey on the Histological Analysis of the Stomach of the Ethanol-Induced Gastric Ulcer Rats

Figure 6 and 7 show the microscopic images of the stomach from the negative control, positive control and KH-treated groups after 30 days.

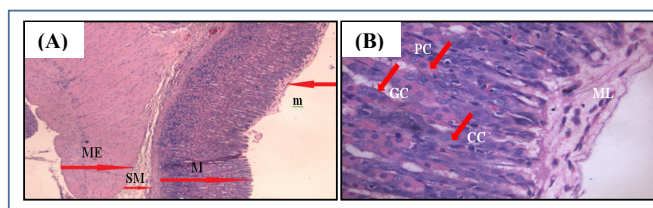


Figure 6. The microscopic images of the stomach from the negative control group; (A) histological analysis of a normal stomach with intact layer of mucosa (M), submucosa (SM), muscularis externa (ME) and the presence of a mucus layer on the epithelium surface (m); (B) histology of the upper portion of the normal stomach/gastric mucosa with a mucus layer (ML) covering its surface
 Note: CC = chief cells; PC = parietal cells; GC = glandular cells. Image A was at 40× magnification, whereas image B was at 400× magnification

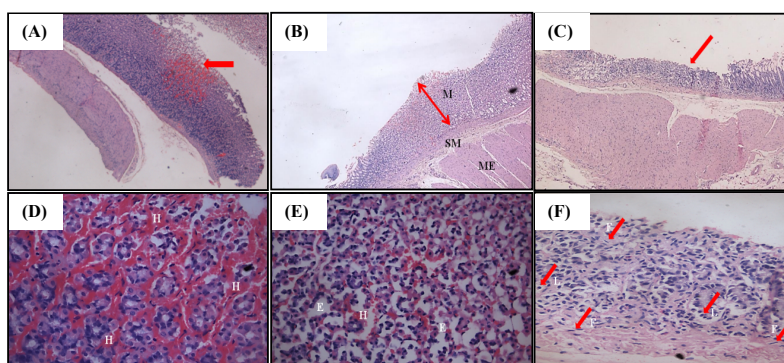


Figure 7. The microscopic images of the stomach from the positive and KH-treated groups; (A) histology of the untreated stomach with focal hemorrhage in the mucosa (arrow); (B) histology of the KH-treated stomach with intact mucosa (M), submucosa (SM) and muscularis externa (ME) layer; (C) histology of the KH-treated stomach with a very thin layer of mucosa resulting from the erosion of the superficial part of the mucosa (arrow); (D) histology of the mucosa layer of the untreated stomach with hemorrhage (H) in the lamina propria. (E) histology of the mucosa layer of the untreated stomach with hemorrhage (H) and edema (E). (F) histology of the remaining part of the mucosa layer of the KH-treated stomach with fibroblast cells (F) and leukocyte infiltration (L)

Note: Images A-C were at 40× magnification, whereas images D-F were at 400× magnification

DISCUSSION

This study was done to evaluate the antiulcer properties of Kelulut honey (KH) in a model of ethanol-induced gastric ulcer in rats. Ethanol has been widely used to induce gastric lesions in experiment animals (Abdulla et al., 2010). The ability of absolute ethanol to induce gastric lesions is related to the formation of free radicals and reactive oxygen species (Nordmann, 1994; Cho et al., 1991). Ethanol has also been reported able to increase lipid peroxidation. Free radicals are able to attack cells, causing damage to the gastric cells of the gastrointestinal tract and leading to erosive lesions and ulceration (Hirokawa et al., 1998).

The results of this study demonstrated the potency of KH in increasing the rats' body weight in all three groups throughout the 30 days of experiment before the rats were induced with ethanol. It was also observed that KH was able to exert antiulcer effects in the ethanol-

induced gastric ulcer model via macroscopic and microscopic evaluation. Diffuse severe hemorrhage was first observed in the positive control group compared to only few areas of mild hemorrhage in the other treatment groups. This was due to the vascular injury caused by the absolute ethanol (Szabo et al., 1995). However, upon treatment with KH, the total ulcer area and ulcer index were reduced compared to the positive control group.

Further histological analysis demonstrated the disruption of the upper mucosal layer, accompanied by severe focal hemorrhage in the negative control group. This was caused by the ability of the ethanol to penetrate the protective mucus layer by dissolving the constituents of the stomach mucus (Szabo, 1987) and subsequently coming into contact with the epithelium surface, causing damage to the cells. It is also reported that severe focal hemorrhage and edema in the lamina propria of the mucosal layer were due to microvascular injury and an increase in vascular permeability as a consequence of microvascular endothelium disruption caused by absolute ethanol (Szabo et al., 1995).

Interestingly, upon pretreatment with KH, no severe hemorrhage or edema was observed in the mucosa. Although vascular congestion was detected, this could have been due to increased blood flow in the gastric mucosa caused by ethanol, leading to hyperemia (Endoh et al., 1993). Nevertheless, hyperemia is not as serious a condition as hemorrhage. The presence of tissue granulation and leukocyte infiltration such as by monocytes and neutrophils in this group could indicate the occurrence of the rapid healing process. The healing process may be divided into three overlapping phases, which are the inflammatory, proliferative and maturation phases (Regan & Barbul, 1994). Leukocyte infiltration such as by circulating monocytes (macrophage) and neutrophils as well as lymphocytes are involved in the inflammatory phase, in which they are crucial for healing (Barbul et al., 1989; Leibovich & Ross, 1975). This is due to the function of the macrophage and neutrophils in removing tissue debris caused by injury. In addition, the presence of fibroblasts in the mucosa cells of the KH pretreated group was an indicator of the proliferative phase of the healing process. Fibroblasts are important in repair processes as they are responsible for the production of structural proteins such as collagen, fibronectin, glycosaminoglycan and hyaluronic acid for the reconstruction of the affected tissue (Regan & Barbul, 1994).

The antiulcer properties of KH suggest that it is high in antioxidant properties. KH, which is from the *Trigona* sp., is intense in colour and high in phenolic content (Kek et al., 2014). Its colour intensity indicates the presence of carotenoids and flavonoids, which are renowned as natural antioxidants (Moniruzzaman et al., 2013b; Saxena et al., 2010), while total phenolic content is one of the reliable parameters for indicating antioxidative activities (Bertoncelj et al., 2007; Beretta et al., 2005; Meda et al., 2005) as well as effectively healing induced gastric ulcers (Bafna & Balaraman, 2005).

CONCLUSION

Kelulut honey was found to be able to increase rats' body weight as well as to possess antiulcer properties that were seen to reduce the total ulcer area and ulcer index in rats with ethanol-induced gastric.

AUTHORS' CONTRIBUTION

LSY supervised, evaluated the data and reviewed the manuscript for publication. RMA analysed the histological slides, while SSSA reviewed the manuscript for publication. NAZ performed the study as her undergraduate final-year project. OYZ, SS, NAE, MFMSZ, TYS, BG and VFL helped with preparation of the experiment studies. FHZA, ASH and AMAM helped with preparation of the manuscript. The authors declare that they have no competing interests.

ACKNOWLEDGEMENT

This work was supported by Universiti Putra Malaysia. The authors also wish to thank all staff of the Biomedical Science Department for help during the study.

REFERENCES

- Abdulla, M. A., Al-Bayaty, F. H., Younis, L. T., & Abu Hassan, M. I. (2010). Anti-ulcer activity of *Centella asiatica* leaf extract against ethanol-induced gastric mucosal injury in rats. *Journal of Medicinal Plants Research*, 4(13), 1253-1259.
- Bafna, P. A., & Balaraman, R. (2005). Anti-ulcer and anti-oxidant activity of pepticare, a herbomineral formulation. *Phytomedicine*, 12(4), 264-270.
- Barakhbah, S. A. S. A. (2007). Honey in the Malay tradition. *Malaysia Journal of Medical Sciences*, 14(1), 106-110.
- Barbul, A., Breslin, R. J., Woodyard, J. P., Wasserkrug, H. L., & Efron, G. (1989). The effect of *in vivo* T helper and T suppressor lymphocyte depletion on wound healing. *Annals of Surgery*, 209(4), 479-483.
- Beretta, G., Granata, P., Ferrero, M., Orioli, M., & Facino, R. M. (2005). Standardization of antioxidant properties of honey by a combination of spectrophotometric/fluorimetric assays and chemometrics. *Analytica Chimica Acta*, 533(2), 185-191.
- Bertoncelj, J., Doberšek, U., Jamnik, M., & Golob, T. (2007). Evaluation of the phenolic content, antioxidant activity and colour of Slovenian honey. *Food Chemistry*, 105(2), 822-828.
- Chan, F. K. L., & Lau, J. Y. W. (2010). Treatment of peptic ulcer disease. In M. Feldman, L. S. Friedman, & L. J. Brandt (Eds.), *Slingers and Fordtrans' gastrointestinal and liver Disease: Pathophysiology/ diagnosis/ management* (pp. 869-884). Philadelphia: Saunders Elsevier.
- Cho, C. H., Pfeiffer, C. J., & Misra, H. P. (1991). Ulcerogenic mechanism of ethanol and the action of sulphanilyl fluoride on rat stomach *in vivo*. *Journal of Pharmacy and Pharmacology*, 43(7), 495-498.
- Clinch, J. (1989). Perinatal mortality 1986 & 1987. *Irish Journal of Medical Sciences*, 158, 148-149.
- Dharmani, P., & Palit, G. (2006). Exploring Indian medicinal plants for antiulcer activity. *Indian Journal of Pharmacology*, 38(2), 95-99.
- Endoh, K., Kao, J., Domek, M. J., & Leung, F. W. (1993). Mechanism of gastric hyperemia induced by intragastric hypertonic saline in rats. *Gastroenterology*, 104, 114-121.
- Goyal, R. K. (2002). *Practical in pharmacology* (pp. 7-10). Ahmedabad: Shah Prakashan.
- Hirokawa, M., Miura, S., Yoshida, H., Kurose, I., Shigematsu, T., Hokari, R. ... & Ishii, H. (1998). Oxidative stress and mitochondrial damage precedes gastric mucosal cell death induced by ethanol administration. *Alcoholism, Clinical and Experimental Research*, 22 (Supplement), 111S-114S.

- Latifah Saiful Yazan, Nurul Amira Zainal, Razana Mohd Ali, Muhamad Firdaus Shyfiq Muhamad Zali, Ong Yong Sze, Tor Yin Sim, Banulata Gopalsamy, Voon Fui Ling, Sarah Sapuan, Nurulaidah Esa, Aminah Suhaila Haron, Fatin Hannani Zakarial Ansar, Ana Masara Ahmad Mokhtar and Sharifah Sakinah Syed Alwi
- Kek, S. P., Chin, N. L., Yusof, Y. A., Tan, S. W., & Chua, L. S. (2014). Total phenolic content and colour intensity of Malaysian honeys from the *Apis spp.* and *Trigona spp.* bees. *Agriculture and Agricultural Science Procedia*, 2, 150-155.
- Kudva, M. V. (1988). Profile of peptic ulcer disease in Malaysia. *Singapore Medical Journal*, 29(6), 544-547.
- Leibovich, S. J., & Ross, R. (1975). The role of the macrophage in wound repair. A study with hydrocortisone and antimacrophage serum. *American Journal of Pathology*, 78(1), 71-100.
- Malferteiner, P., Chan, F. K., & McColl, K. E. (2009). Peptic ulcer disease. *Lancet*, 374(9699), 1449-1461.
- Mathers, C., Fat, D. M., & Boerma, J. T. (2008). The global burden of disease: 2004 update. *World Health Organization* (pp. 1-133). Switzerland: World Health Organization.
- Meda, A., Lamien, C. E., Romito, M., Millogo, J., & Nacoulma, O. G. (2005). Determination of the total phenolic, flavonoid and proline content in Burkina Fasan honey, as well as their radical scavenging activity. *Food Chemistry*, 91(3), 571-577.
- Moniruzzaman, M., Sulaiman, S. A., Khalil, M. I., & Gan, S. H. (2013). Evaluation of physicochemical and antioxidant properties of sourwood and other Malaysian honeys: A comparison with Manuka honey. *Chemistry Central Journal*, 7, 1-12.
- Naesdal, J., & Brown, K. (2006). NSAID-associated adverse effects and acid control aids to prevent them: A review of current treatment options. *Drug Safety*, 29, 119-132.
- Nordmann, R. (1994). Alcohol and antioxidant systems. *Alcohol and Alcoholism*, 29(5), 513-522.
- Ouchemoukh, S., Louaileche, H., & Schweitzer, P. (2007). Physicochemical characteristics and pollen spectrum of some Algerian honeys. *Food Control*, 18(1), 52-58.
- Pillai, S. I., Kandaswamy, M., & Subramanian, S. (2010). Antiulcerogenic and ulcer healing effects of Indian propolis in experimental rat ulcer models. *Journal of ApiProduct and ApiMedical Science*, 2, 21-28.
- Rang, H. P., Ritter, J. M., Flower, R. J., & Henderson, G. (2014). *Rang & Dale's pharmacology: With student consult online access*. Elsevier Health Sciences.
- Regan, M. C., & Barbul, A. (1994). The cellular biology of wound healing. *Wound Healing* (pp. 3-17). New York: Springer-Verlag.
- Sandhya S., Venkata, R. K., Vinod, K. R., Reddy, S., & Begum, A. (2013). Scope of medicinal flora as effective anti-ulcer agents. *African Journal of Plant Science*, 7(11), 504-512.
- Saxena, S., Gautam, S., & Sharma, A. (2010). Physical, biochemical and antioxidant properties of some Indian honeys. *Food Chemistry*, 118(2), 391-397.
- Szabo, S. (1987). Mechanisms of mucosal injury in the stomach and duodenum: Time sequence analysis of morphologic, functional, biochemical and histochemical studies. *Scandinavian Journal of Gastroenterology*, 22(S127), 21-28.
- Zainol, M. I., Yusoff, K. M., & Yusof, M. Y. M. (2013). Antibacterial activity of selected Malaysian honey. *BMC Complementary and Alternative Medicine*, 13(1), 1-10.